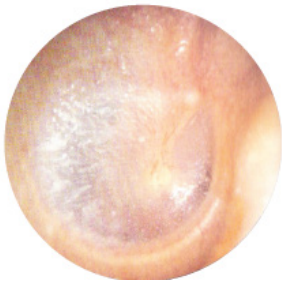
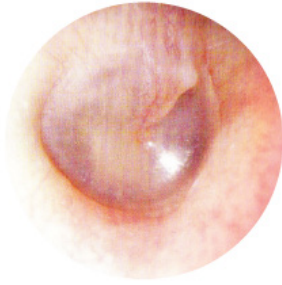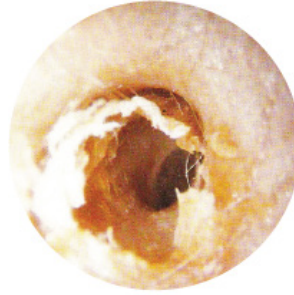


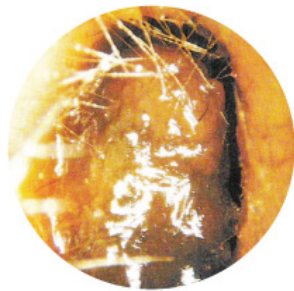NORMAL EARS



WAX BUILD-UP

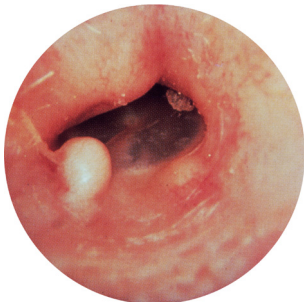


Normal wax.

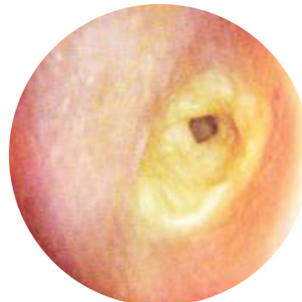


Excessive wax.

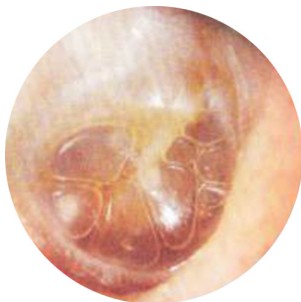ABNORMAL EARS



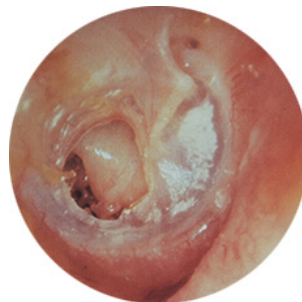Exostoses.
Swimmer's ear.
Bony growth under skin.



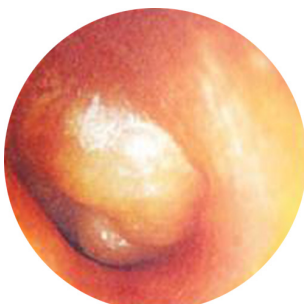Otitis externa.
Infected ear canal.



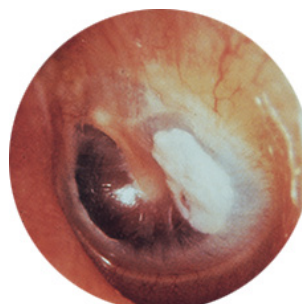
Non suppurative otitis media.
"Glue Ear".
Eustachian tube dysfunction leading to build-up of fluid in the middle ear.



Perforation of the tympanic membrane.
Possible infection risk.



Suppurative otitis media.
"Glue Ear" with bacterial infection.



Tympanosclerosis.
Scar tissue or thickening of tympanic membrane.